



---

## Original Research Paper

---

### **Anatomical Variations of the Circle of Willis as seen at the University Teaching Hospital, Lusaka, Zambia.**

Hilda Zulu<sup>1</sup>, Patience N. Buumba<sup>1</sup>, Moono Silitongo<sup>2</sup>, Krikor Erzingastian<sup>3</sup>, Boyd Mudenda<sup>4</sup>

<sup>1</sup> Department of Anatomy, School of Medicine, University of Zambia, Lusaka, Zambia.

<sup>2</sup> Department of Basic Sciences, School of Medicine, Copperbelt University, Ndola, Zambia

<sup>3</sup> Departments of Surgery and Anatomy, School of Medicine, University of Zambia, Lusaka, Zambia

<sup>4</sup> Department of Public Health, School of Medicine, University of Zambia, Lusaka, Zambia.

Email: [hildazulu2000@yahoo.co.uk](mailto:hildazulu2000@yahoo.co.uk)

#### **To cite this article:**

Hilda Zulu, Patience N. Buumba, Moono Silitongo, Krikor Erzingastian, Boyd Mudenda. Anatomical Variations of the Circle of Willis as seen at the University Teaching Hospital, Lusaka, Zambia. *Journal of Preventive and Rehabilitative Medicine*, Vol. 1, No. 2, 2016, pp. 61-66. doi: 10.21617/jprm.2016.0102.12

---

#### **ABSTRACT**

**Background:** The ideal distribution of blood to the brain and the collateral potential of the Circle of Willis (CW) is believed to be dependent largely on the morphology and the presence of all the component vessels of the CW. Several studies have shown that variations in the CW play an important role in the development of cerebrovascular diseases (CVD) such as cerebrovascular accidents or stroke, aneurysms and infarctions. Despite these CVDs being on the increase, no study on anatomical patterns or variations has been conducted in the local and sub-regional population. The study aimed to determine the anatomical variations of the CW as seen at the University Teaching Hospital, Zambia.

**Methods:** The study was undertaken to observe the morphology of the CW using gross dissection in 185 post mortem non pathological brains. A data collection form was used to capture information such as age, sex, external diameter of the posterior communicating arteries (PcoA) and aneurysms. Univariate and multivariate analysis was used to determine factors associated with hypoplasia of both left and right PcoA. Statistical analysis was performed with STATA version 12.

**Results:** This study showed that 90.3% of the brain specimen had complete circles. Hypoplasia (< 1mm diameter) was 30.3% and 36.2% in the right and left PcoA respectively. The proportion of males 149 (80.5%) were significantly higher ( $p < 0.0001$ ) than females 36 (19.5%). The median age for individuals with hypoplasia (<1.0mm) of the right and left PcoA was 48 and 46 years respectively; the medians were statistically different ( $p < 0.0001$ ). A significant association between age and hypoplasia of the PcoA was observed ( $p < 0.001$ ).

**Conclusion:** The study revealed significant variations in the CW in the brain specimens studied at the University Teaching Hospital, Zambia. Hypoplasia in the PcoA was the most common noted variation with CW incompleteness in a few cases. No aneurysm was observed.

**Key words:** Circle of Willis, Anatomical Variations, Hypoplasia, Post-mortem

---

## **1. Introduction**

The brain is supplied by two internal carotid arteries and two vertebral arteries that form a complex anastomosis, the Circle of Willis (CW) at the base of the brain. [1]. The CW is a polygonal structure of collateral blood vessels (Figure1) located in the subarachnoid space within the interpeduncular cistern. The CW vessels diverge from this anastomosis to

distribute oxygen-rich arterial blood to various cerebral regions [2].

Anteriorly, the two internal carotid arteries branch at the medial end of the Sylvian fissure to form the middle and anterior cerebral arteries, with the two anterior cerebral arteries joined at the anterior end of the longitudinal fissure by the small anterior communicating artery which supply blood

Hilda Zulu, Patience N. Buumba, Moono Silitongo, Krikor Erzingastian, Boyd Mudenda. *Anatomical Variations of the Circle of Willis* to the front and the sides of the brain. Posteriorly, there are two posterior cerebral arteries, formed by the division of the basilar artery, joined to the ipsilateral internal carotids by a posterior communicating artery. These perfuse and supply the posterior aspect of the brain [1].

The ideal distribution of blood to the brain and the collateral potential of the CW is believed to be dependent largely on the morphology and the presence of all the component vessels of the CW [3]. However, there is a considerable individual variation in the pattern and calibre of vessels that make up the CW. Different anomalies such as absence, split, hypoplastic (< 1mm diameter) and accessory vessels had been observed [4,21]. These anomalies are frequent in the anterior and posterior communicating arteries since these arteries are designated as primary collateral pathways [5]. In light of this the integrity of the CW may be compromised because anomalies and hypoplasia in the anterior and posterior communicating arteries of the CW are common [6].

Furthermore, the anatomical variations such as absence, hypoplasia and aneurysms that had been observed in the CW may affect the occurrence and severity of symptoms of cerebrovascular diseases (CVD) such as cerebrovascular accidents or stroke, aneurysms and infarctions among others [7]. Identification of such variations using Magnetic resonance angiography (MRA) and computerized tomographic angiograms (CT) in a specific population is therefore important in the evaluation of cerebral vascular morbidity for appropriate management [8].

Magnetic resonance angiography and CT angiography exhibits the functional morphology of the CW and also offers a useful means for hemodynamic assessment of blood flow and direction through different techniques and procedures [5]. There is a definite correlation between the anomalies of CW (absent, split, hypoplastic and accessory vessels), especially asymmetrical PcoA, asymmetric proximal segments of the anterior cerebral artery (ACA) and aneurysms on the vessels of the CW [9]. Although the cause of cerebral hemorrhage is multifactorial, the variations in CW play a role in hemorrhagic strokes [9].

To this effect, knowing the state of the circle becomes vital to neurosurgeons in patient selection in order to determine the adequacy of the brain circulation in operations for cerebral aneurysms and also in ligation of the internal carotid artery [10]. The fact that no such a study has been conducted in the local and sub-regional population as well as the increase in the incidence of CVD, the study on variations in the CW anatomy was undertaken. This study may also have special value in future research to ascertain influence of genetic, racial, regional, environmental and hemodynamic factors [8].

## 2. Methodology

### Study design and population

This cross sectional study determined the prevalence of variations in 185 post mortem brains at the University Teaching Hospital in Lusaka city, Zambia. The formula for determining the sample size for prevalence studies was used

to estimate the sample size. The assumption for the sample size was obtained from a cross section study conducted in Sri Lanka similar to the one adapted in this study. The prevalence of a typical CW in the Sri Lankan study was 14% [11] giving a prevalence of the variation used in this study to be 86% or  $1 - 0.14 = 0.86$ . All brains from human cadavers that underwent post-mortem and did not show evidence of pathology or trauma (severe haemorrhage, tissue damage and mass lesions) of the brain and its blood supplying vessels were included in the study.

### Data collection

Data was collected immediately after removal of the brain from the cranial cavity. Dissection was done to expose the CW and photographs taken. The CW was studied in each specimen with reference to parameters such as completeness, aneurysms and external diameter of the PcoA. Only the PcoA external diameter was measured since variations such as hypoplasia and absence are most common in these vessels [12, 6].

A digital vernier calliper was used to measure external diameter of the PcoA while aneurysms and presence/ absence of component vessels to describe completeness /incompleteness were observed. A data collection form was formulated and was used to capture information such as age, sex, external diameter of PcoA and aneurysms. The brain specimen was placed back into the cranium upon completion of the examination. Ethical approval for the study was obtained from Excellence in Research Ethics and Science Converge Institutional Review Board, Zambia (Ref. No. 2015-July 00005948). This study was performed as part of the routine postmortem examinations and to this effect, the consent used was that obtained by Pathologists.

### Data analysis

The analysis of the anatomical pattern and variations of the CW was performed using STATA (STATA CORP, version 12, College Station, Texas, USA). A two sample test of proportion for gender was used giving an equal proportion of male and female. To test for differences in the median, two sample Wilcoxon Rank Sum (Mann Whitney) test was used. The median diameter was chosen to describe hypoplasia with a cut off of point less than 1mm. Univariate and multivariate analysis was used to determine factors associated with hypoplasia of both left and right PcoA. All statistical tests were performed at 5% significance level or 95% confidence interval with p-value of <0.05 to determine statistical significance.

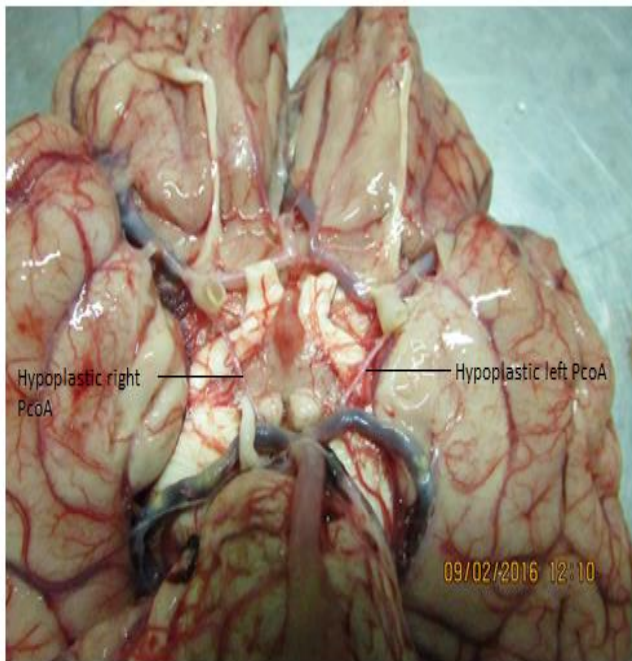
## 3. Results

The total sample size was 185 of human cadavers with the median age of 37 years (range; 17-86). The proportion of males 149 (80.5%) were significantly higher ( $p < 0.0001$ ) than females 36 (19.5%). The median age for individuals with hypoplasia (<1.0mm) of the right PcoA was 48 years (range; 17-86 years) and those without it was 34 years (17-72 years); the medians were statistically different ( $p < 0.0001$ ). In case of hypoplasia of the left PcoA, the median age for the affected was 46 years (range; 17-86 years) and those unaffected was 33 years (range; 17-75 years); there was a statistical difference, p

< 0.0001. Average values and the standard deviations for right and left PcoA were 1.4 ( $\pm 0.8$ ) mm and 1.3 ( $\pm 0.7$ ), respectively.

The means and standard deviations for males and females with regards to right and left PcoA were 1.4 ( $\pm 0.8$ ) mm and 1.3 ( $\pm 0.7$ ) mm and 1.4 ( $\pm 0.7$ ) mm and 1.4 ( $\pm 0.6$ ), respectively. However, the t-test showed that there was no statistical difference in the means of both right ( $p = 0.7191$ ) and left ( $p = 0.6650$ ) side of the PcoA with respect to gender.

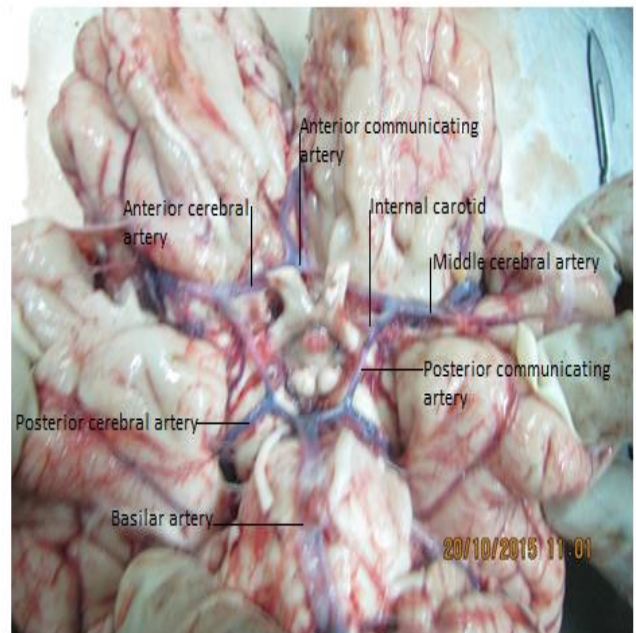
This study showed that 90.3% of the brain specimen had complete circles (figure 2). Hypoplasia (< 1mm diameter) was 30.3% and 36.2% in the right and left PcoA respectively (figure 1). Multivariate analysis showed that one unit increase in age statistically increased the likelihood of having hypoplasia of the left and right PcoA by 9% and 10% respectively. However, of all the human cadavers examined, no aneurysm was observed.



**Figure 1** showing bilateral hypoplasia of the PcoA with diameters less than 1mm measured during post-mortem examination

**Table 1: Basic Characteristics of the study variables**

Characteristics	N (%)
Total	185 (100%)
<b>Gender</b>	
Male	149 (80.5)
Female	36 (19.5)
<b>PcoA Rt</b>	
< 1.0mm	56 (30.3)
$\geq 1.0$ mm	129 (69.7)
<b>PcoA Lt</b>	
< 1.0mm	67 (36.2)
$\geq 1.0$ mm	118 (63.8)
<b>Circle of Willis</b>	
Complete	167 (90.3)
Incomplete	18 (9.7)
<b>Aneurysm</b>	
Yes	0 (0.0)
No	185 (100%)



**Figure 2** showing a complete circle: Posterior part: All components, PcoA, posterior cerebral artery (PCA) and basilar artery present (BA); normal in their origin and size. Bifurcation of BA is equal and symmetric. Anterior part: all the components, anterior cerebral (A1) segment and anterior communicating artery (ACoA) present; normal in their origin and size.

**Table 2: Factors associated with left and right posterior communicating arteries**

Characteristics	Univariate analysis		Multivariate analysis	
	OR (95%CI)	P-value	OR (95%CI)	P-value
Hypoplasia for left PcoA				
<b>Age</b>	1.08 (1.05, 1.11)	< 0.001**	1.09 (1.06, 1.12)	< 0.001**
<b>Gender</b>				
Male	0.00	0.00	0.00	0.00
Female	0.52 (0.23, 1.19)	0.123	0.28 (0.10, 0.80)	0.017**
Hypoplasia for right PcoA				
<b>Age</b>	1.09 (1.06, 1.13)	< 0.001**	1.10 (1.06, 1.13)	< 0.001**
<b>Gender</b>				
Male	0.00	0.00	0.00	0.00
Female	1.02 (0.46, 2.24)	0.967	0.70 (0.26, 1.88)	0.477

Abbreviations: OR = odds ratio; CI = confidence interval; PcoA = posterior communicating artery; \*\*p-value < 0.05

### Factors associated with hypoplasia

Univariate and multivariate analysis (Table 2) shows the factors associated with hypoplasia for both left and right PcoA. A multivariate analysis showed that one unit increase in age statistically increased the likelihood of having hypoplasia of the left PcoA by 9% (OR 1.09; 95%CI 1.06, 1.12;  $p < 0.001$ ). At univariate analysis, gender was not associated with hypoplasia of the left PcoA (OR 0.52; 95% CI 0.23, 1.19;  $p = 0.123$ ). However, during multivariate analysis, females had a statistically reduced odds of having hypoplasia of the left PcoA by 72% (OR 0.28; 95%CI 0.10, 0.80;  $p = 0.017$ ) compared to their male counterpart. Hence, making age and gender as the factors associated with hypoplasia of the left PcoA.

In case of hypoplasia of the right PcoA, multivariate analysis showed that a unit increase in age statistically increased one's odds of having hypoplasia by 10% (OR 1.10; 95% CI 1.06, 1.13;  $p < 0.001$ ). Gender was not statistically significant at both univariate and multivariate analysis (OR 1.02; 95%CI 0.46, 2.24;  $p = 0.967$  and OR 0.70; 95%CI 0.26, 1.88;  $p = 0.477$ ). Therefore, making age as the only variable associated with hypoplasia of the right PcoA.

## 4. Discussion

In this present study a high prevalence of CW completeness was observed (90.19%). This was compared to studies in India (48%) [7, 4] and Egypt (46.7%) [13], in which almost half of the circles were complete. On the other hand, a study in Sri Lanka found [14] a low prevalence of completeness in the CW (14.2%). The wide range in the prevalence of the typical configuration could be attributed to the influence of genetic, regional, environmental, hemodynamic factors and also the diversity in the classification of hypoplastic vessels [7].

In this study the CW was considered complete if all the component vessels were present, whether hypoplastic or duplicated but not absent. This was based on the classification system that focuses on the continuity of the circular configuration (morphological completeness) that measures the potential for collateral flow development [5]. On the other hand the CW was found to be incomplete in a few cases and this was mostly due to absence of the PcoA unilaterally or bilaterally. This incompleteness could pose a risk factor for ischaemic stroke especially in internal carotid occlusion [8].

### Hypoplasia in the posterior communicating arteries

The PcoA connects the two systems that supply the brain (internal carotid and vertebro-basilar systems). Therefore, making the PcoA very important vessels and worthwhile to study since they provide collaterals in the cerebral circulation so that if one system is blocked, the other can take over [15]. To define hypoplasia of the PcoA, various authors used different measurement. In the present study, the vessel was considered hypoplastic if the external diameter was less than 1mm, chosen based on various autopsy studies [16, 12, 4, 21].

Variations in the PcoA are regarded as the most common variations in brain circulations. They are either hypoplastic or missing in 10% to 46% of the cases [12, 6]. Similarly, in the present study, hypoplasia was seen in 30.3% and 36.2% in the left and right PcoA respectively. Absent vessels were seen in 9.7% which is consistent with the reported incidence of absent vessels, usually the PcoA ranging from 0.6% to 17% in the CW leading to circle incompleteness [7]. These results confirm that the greatest variation in calibre between individuals occurs in the PcoA, which is normally very small, so that only limited flow is possible between the anterior and posterior circulations [2].

According to most literature, hypoplasia of PcoA is a congenital variation and does not lead to any symptoms if other component vessels of the CW are functioning normally. This observation could explain its presence in otherwise

Hilda Zulu, Patience N. Buumba, Moono Silitongo, Krikor Erzingastian, Boyd Mudenda. Anatomical Variations of the Circle of Willis normal persons. However, PcoA becomes a risk factor in ischaemic stroke in the presence of internal carotid artery (ICA) occlusion [17]. It has been emphasised that anomalies of the PcoA have a great significance since it forms a link between two major arterial systems [14]. Consequently, a hypoplastic PcoA may be a risk factor for developing neurological deficit in patients with ICA occlusion. A definitive correlation between narrow or absent PcoA and cerebral infarction in persons with ICA occlusion has also been observed [18]. Ultimately, studying the variability of the PcoA is important for academic reasons and in clinical practice since variations can influence the mode of presentation, plan of investigation and treatment of various neurological disorders [14].

### Factors associated with hypoplasia

In the present study, a significant association was observed between age and hypoplasia of the PcoA. However, gender was only statistically significantly associated with hypoplasia of the left PcoA. It was established that one unit increase in age statistically increased the likelihood of having hypoplasia by 9% and 10% for left and right PcoA respectively. This was consistent with findings in the United States America where they found Larger PcoA to be more in children (39–75%) than in adults (8–29%) [19]. This observation supports the notion that the calibre of this vessel could diminish with age.

In contrast, a study conducted in Serbia found the smallest calibre of the right and left PcoA (0.30 and 0.45 mm) in a 44-year-old and in a 64-year-old woman, while the largest calibre (2.86 and 3.31 mm) was found in an 80-year old woman [20]. This observation can be explained in line with literature that states that segments of the CW which are narrow or string-like, or even absent are a result of agenesis or involution during embryonic development [21]. Gender however, was not associated with hypoplasia of the right PcoA, but at multivariate analysis it was found to be a factor associated with hypoplasia of the left PcoA only.

### 5. Conclusion

The study reveals that there were significant variations in the CW in the brain specimens studied at the University Teaching Hospital in Zambia. Hypoplasia (< 1mm diameter) in the right and left PcoA (30.3% and 36.2% respectively) was the most common noted variation. A significant association between age and hypoplasia of the PcoA was observed. However, a high prevalence in the completeness of the CW (90.3%) and no aneurysm was noted.

### Limitation of the study

The limitation for this study was the possible change that could have occurred in the diameter of the vessels during postmortem which could have affected the measurements.

### Acknowledgement

The authors wish to thank, University Teaching Hospital Managing Director, Head of Anatomy Department, Head of Pathology Department, the Pathologists and Pathology

Assistants for the help rendered during data collection. Other acknowledgements go to Benson Hamoonga and Brian Chiluba for the guidance in statistical analysis.

### REFERENCES

1. Moorehead KT, Moore SM, Chase JG, David T & Fink J. "3D models of auto-regulated cerebrovascular flow". *J Biomech Eng.* 2005; 127: 440-449.
2. Standring S. Gray's Anatomy, "The anatomical basis of clinical practice". 40th ed; 2008; Oxford: Churchill Livingstone, Elsevier.
3. Paul S & Mishra S. "Variations of the anterior cerebral artery in human cadavers: a dissection study. *J Anat Soc India 2004*; 53(1):15-16. Retrieved 20/12/2014 from <http://www.medind.in/jae/t04ii1p15.pdf>
4. Kapoor K, Singh B & Dewan LIJ. "Variations in the Configuration of the Circle of Willis". *Anatomical Science International 2008*; 83(2):96-106. Retrieved 25/12/2014 from <http://www.ncbi.nlm.nih.gov/pubmed/18507619>
5. Hartkamp MJ, Van der Grond J, Van Everdingen KJ, Hillen B & Mali WPTM. "Circle of Willis Collateral Flow Investigated by Magnetic Resonance Angiography". *AHA journals 1999*; 30(12): 2671-2678. Retrieved 01/04/2015 from <http://stroke.ahajournals.org>
6. Merkkola P, Tulla H, Ronkainen A, Soppi V, Oksala A, Koivisto T & Hippeläinen M. "Incomplete Circle of Willis and Right Axillary Artery Perfusion". *The Annals of Thoracic Surgery 2006*; 82(1):74–80.
7. Iqbal S. "A Comprehensive Study of the Anatomical Variations of the Circle of Willis in Adult Human Brains. *J Clin Diagn Res 2013*; 7(11):2423–2427. Available on [www.ncbi.nlm.nih.gov/pubmed/24392362](http://www.ncbi.nlm.nih.gov/pubmed/24392362)
8. Hoksbergen AWJ, Fulesdi B, Legemate DA & Csiba, L. "Collateral Configuration of the Circle of Willis Transcranial Color-Coded Duplex Ultrasonography and Comparison with Postmortem Anatomy 2003", 31(6):1346-1351. Retrieved from [www.ncbi.nlm.nih.gov/pubmed/10835455](http://www.ncbi.nlm.nih.gov/pubmed/10835455).
9. Siddiq H, Tahir M. & Khalid LKP. "Variations in Cerebral Arterial Circle of Willis in Adult Pakistani Population". *Journal of college of Physicians and Surgeons Pakistan 2010*; 23 (9): 615-619. Retrieved from [www.ncbi.nlm.nih.gov/pubmed/24034183](http://www.ncbi.nlm.nih.gov/pubmed/24034183)
10. Sande V & Wanjari SP. "Variations in the Arterial Circle of Willis in Cadaver: A Dissection study. *IJHSR 2014*; 4(8):132-138. Retrieved 02/01/2015 from <http://www.scopemed.org/?mno=166883>.
11. De Silva RKR, Silva R, Amaratunga D, Gunasekera, WSL & Jayesekera RW. "Types of the cerebral arterial circle (circle of Willis) in a Sri Lankan Population". *BMC Neurol. 2011*; 11 (5):1-8. Retrieved 17/02/2015 from <http://www.biomedcentral.com/1471-2377/11/5>.
12. Eftekhari B, Dadmehr M, Ansari S, Ghodsi M, Nazparvar B & Ketabchi E. "Are the distributions of variations of circle of Willis different in different populations"? Results of an Anatomical Study and Review of Literature. *BMC Neurol. 2006*; 24(6): 22-31. Retrieved 24/12/2014 from <http://www.biomedcentral.com/1471-2377/6/22>.

13. Maally MA & Ismail AA. "Three dimensional magnetic resonance angiography of the circle of Willis: Anatomical variations in general Egyptian population". *The Egyptian journal of radiology and nuclear medicine* 2011; 42:405-412. Retrieved 21/02/2015 from <http://www.sciencedirect.com/science/journal/0378603x>
14. Saha A, Bhagyalakshmi B, Mandal S & Banopadhyaya M. Variation of posterior communicating artery in human brain: a morphological study. *Gomal J Med Sci.* 2013; 11:42–46.
15. Ardakani SK, Dadmehr M, Nejat F, Ansari S, Tajik BE & Khashab ME. "The cerebral arterial circle (Circulus Arteriosus Cerebri): an anatomical study in fetus and infant samples". *Pediatr Neurosurg.* 2008; 44:388-392.
16. Wu H & Chuang Y. "The Clinical Relevance of Fetal Variant of the Circle of Willis and Its Influence on the Cerebral Collateral Circulation". *Acta Neurol Taiwan* 2011; 20 (4): 232-242.
17. Schomer DF, Marks, MP, Steinberg G.K, Johnstone IM, Boothroyd DB, Ross MR, Pelc NJ & Enzmann DR. "The anatomy of the posterior communicating artery as a risk factor for ischemic cerebral infarction". *N Engl J Med.* 1994; 330: 1565-1570.
18. Baskaya MK, Coscarella E, Gomez F & Morcos JJ. "Surgical and angiographic anatomy of the posterior communicating and anterior choroidal arteries". *Neuroanatomy journal.* 2004; 3: 38–42.
19. Vasović L, Trandafilović M, Jovanović I, Ugrenović S, Vljaković S & Stojanović J. "Types and Subtypes of the Posterior Part of the Cerebral arterial Circle in Human Adult Cadavers". 2011; 16:359-382.
20. Saikia B, Handique A, Phukan P, Lynser D & Sarma A. Circle of Willis: Variant forms and their embryology using gross dissection and magnetic resonance angiography. *Int J Anat Res* 2014; 2(2):344-53.
21. Tanaka H, Fujita N, Enoki T & Matsumoto K. "Relationship between variations in the circle of Willis and flow rates in internal carotid and basilar arteries determined by means of magnetic resonance imaging". *Am J Neuroradiol.* 2006; 27: 1770-1775.